

# Symmetric Diffuse Lipomatosis of the Thyroid Gland

VIJAY D. DOMBALE, ANITA P. JAVALGI, KALBURGI

## ABSTRACT

Diffuse lipomatosis is a benign lesion of the thyroid gland with very few cases being documented in the literature. We present a case of a 62 yr old male who presented with a midline neck swelling of 6 months duration and respiratory stridor since few days. After the clinical examination, a provisional diagnosis of nodular goitre was made and the patient was sent for cytological study. Fine needle aspiration cytology studies reported it as a

benign follicular epithelial lesion. A near total thyroidectomy was done and the specimen was sent for histopathological studies. Multiple sections from both the lobes revealed the diffuse infiltration of the adipose tissue into the thyroid stroma. There was no evidence of amyloid deposits. Other causes of the fat deposits were ruled out. The case was reported as diffuse lipomatosis of the thyroid, a rare finding with only few cases being reported in the literature.

**Key Words:** Lipomatosis, Thyroid gland, Diagnosis

## INTRODUCTION

The presence of mature adipose tissue in the central portion of the thyroid gland is extremely rare. Diffuse adipose tissue infiltration into the thyroid stroma is termed as thyrolipomatosis [1]. Thyrolipoma is a well encapsulated thyroid adenoma with fatty tissue deposits [1, 2].

Diffuse lipomatosis being the rarest with 11 cases in literature [1]. Here, we present a case of thyrolipomatosis in a 62 yr old male who presented with respiratory distress.

## CASE REPORT

A 62yr old male presented to the surgery OPD with a gradually increasing midline neck swelling of 6 months duration with a recent onset of respiratory discomfort while breathing. On local examination, a large midline neck swelling was found, which moved with deglutition. All routine haematological investigations and thyroid function tests showed normal results. Sonography showed a diffused thyroid enlargement (regret no pictures). Fine needle aspiration cytology revealed a hypocellular smear which was composed of benign follicular epithelial cells with scattered adipocytes and the case was reported as a benign follicular lesion of the thyroid (Table/Fig-1 & 2). A near total thyroidectomy was done. There were no adhesions and no difficulty was experienced during the operation. Both the lobes of the thyroid gland were removed easily and were sent for histopathological studies.

## Gross

Received both the lobes of the thyroid gland. The right lobe weighed 165gms and measured 12×10×6cms and the left lobe weighed 120 gms and measured 15×8×6cms. Both the lobes were soft in consistency.

The external appearance was pale gray nodular and the cut surface was diffuse pale yellow with a faint lobular appearance [Table/Fig-3].

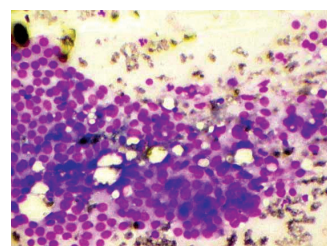
## Microscopy

Thyroid follicles of variable size which were lined by cuboidal epithelium which was filled with colloid were revealed. The intervening stroma showed a diffuse extensive infiltration of mature adipose tissue with scanty focal lymphocytic infiltration. There was no evidence of amyloid deposits [Table/Fig-4 & 5].

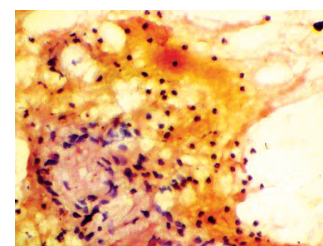
The case was diagnosed as diffuse lipomatosis of the thyroid gland.

## DISCUSSION

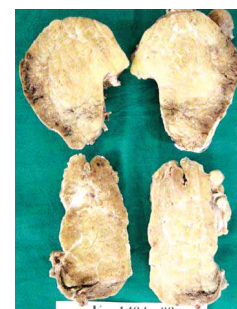The presence of adipose tissue is commonly seen in the salivary gland, parathyroid, thymus or pancreas but it is unlikely to be seen in the thyroid gland. A small amount of mature fat is rarely found



**[Table/Fig-1]:** Leishman stain 100× Follicular cells noted along with fat globules in between

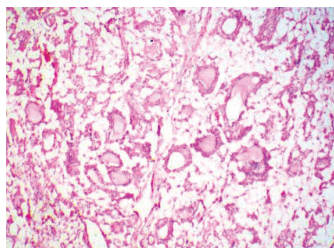


**[Table/Fig-2]:** H&E stain 100× Thyroid follicles seen with fat globules and lymphocytes in background

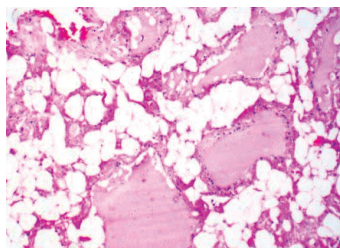


**[Table/Fig-3]:** Gross picture

Two lobes of thyroid seen right lobe m 12×10×6 cms & weighing 165 gms & left lobe in 15×8×6 cms & weighing 120 gms.



**[Table/Fig-4]:** H&E 100×  
Thyroid follicles with stroma showing  
mature adipose tissue



**[Table/Fig-5]:** H&E 400×  
Follicles filled with colloid & stroma  
showing mature adipose tissue

around the blood vessels in the subcapsular area of the anterior portion of the thyroid gland [3, 4, 5].

Diffuse thyrolipomatosis is a rare entity which was first reported by Dhayagude in 1942 [6].

The presence of adipose tissue in the thyroid gland can be considered as thyrolipoma, a fat containing thyroid follicular adenoma, with complete fibrous encapsulation. On the other hand, thyrolipomatosis is characterised by diffuse fatty infiltration in the thyroid stroma with no evidence of encapsulation or it may be the heterotopic nests of fat cells in the thyroid characterised by the restrictive subcapsular location [1]. The exact mechanism has not been determined [7]. Schroder et al have postulated that the adipose tissue may be derived from metaplasia of the stromal fibroblasts in response to tissue hypoxia or to senile involution, as demonstrated in the organs<sup>8</sup>. Chesky et al and other authors have attributed the lesions to the simultaneous inclusion of fat with striated muscle in the thyroid gland during embryogenesis before the development of the thyroid capsule [9, 10].

The most common age group which is affected is the middle aged group, with no sex predilection, but the possibility of congenital goitre with fatty change cannot be ruled out [1].

The differential diagnosis includes amyloid goitre, lymphocytic thyroiditis, intra thymic or parathyroid lipoma, encapsulated papillary carcinoma, liposarcoma and lipid rich clear cell adenoma [1, 3].

Amyloid goitre is usually associated with systemic amyloidosis which stains intensely with crystal violet and Congo red [4]. Lymphocytic

thyroiditis shows diffuse lymphocytic stromal infiltration [3]. The presence of cytoplasmic glycogen favours the parathyroid tissue in case of parathyroid lipoma [1]. Papillary carcinoma has characteristic histomorphological features and liposarcoma is a very aggressive, rapidly growing tumour mass [3]. Clear cell adenoma with lipid rich shows follicular cells with small round nuclei and abundant foamy to coarsely vacuolated cytoplasm [1].

In the present case, a 62yrs old man presented with a diffuse enlargement of the thyroid gland. His condition was euthyroid. Fine needle aspiration cytology showed the presence of adipocytes along with follicular cells, but it was unable to co-relate the presence of adipocytes. Finally, based on histomorphological studies, a diagnosis of diffuse lipomatosis of the thyroid was made.

## CONCLUSION

Diffuse lipomatosis, also called choriostomatous adiposity [3], which demonstrating diffuse fatty infiltration in the thyroid stroma, is an extremely rare entity. Radiological and cytological studies were not diagnostic but histopathological studies confirmed the diagnosis.

This case was presented for its rarity.

## REFERENCES

- [1] Yimin et al. Thyrolipoma and thyrolipomatosis: 5 case reports and historical review of the literature. *J Ann Diag Path* 2009; 13:384-389.
- [2] Borges A, Catarina A. Case 53: adenolipoma of the thyroid gland. *Radiology* 2002;225:746-50.
- [3] Gupta R et al . Diffuse lipomatosis of the thyroid gland – a pathological curiosity. *Indian J Path Microl* 2009;52(2):215-16.
- [4] Aksu AO, Mustafa N. Diffuse fatty infiltration of the thyroid gland in amyloidosis. *J Ultrasound Med* 2010;29:1251-1255.
- [5] Gupta A, Mathur SK. Adenolipoma of the thyroid gland. *Indian Journ Path Microl* 2008;51(4):521-522.
- [6] Dhayagude RG. Massive fatty infiltration in a colloid goitre. *Arch Pathol* 33:357-360.
- [7] Gnepp DR, Ogorzalek JM, Heffess CS. Fat containing lesions of the thyroid gland. *Am J Surg Pathol* 1998;13:605-12.
- [8] Schroder S, Bocker W. Lipomatous lesions of the thyroid gland; a review. *Appl Pathol* 1985; 3:140-9.
- [9] Chesky VE, Dreese WC, Hellwig CA. Adenolipomatosis of the thyroid: a new type of goitre. *Surgery* 1953; 34:38-45.
- [10] Waffe RH. Histological studies on the fat content in the normal human heart. *Arch Pathol* 1927;3:955-62.

### AUTHOR(S):

1. Dr. Vijay D. Dombale
2. Dr. Anita P. Javalgi
3. Dr. Kalburgi

### PARTICULARS OF CONTRIBUTORS:

1. Corresponding Author
2. Post graduate in Dept of pathology, SN medical college Bagalkot, Karnataka, India.
3. Professor & HOD of Dept of surgery, SN medical college Bagalkot, Karnataka, India.

### NAME, ADDRESS, TELEPHONE, E-MAIL ID OF THE CORRESPONDING AUTHOR:

Dr. Vijay D. Dombale  
B-2 staff quarters  
SN Medical College Bagalkot - 587101, Karnataka.  
Phone: 09480598017; E-mail: drvijay@gmail.com

### DECLARATION ON COMPETING INTERESTS:

No competing Interests.

Date of Submission: **Feb 21, 2011**  
Date of Peer Review: **Mar 30, 2011**  
Date of Acceptance: **Jul 07, 2011**  
Date of Publishing: **Aug 08, 2011**